


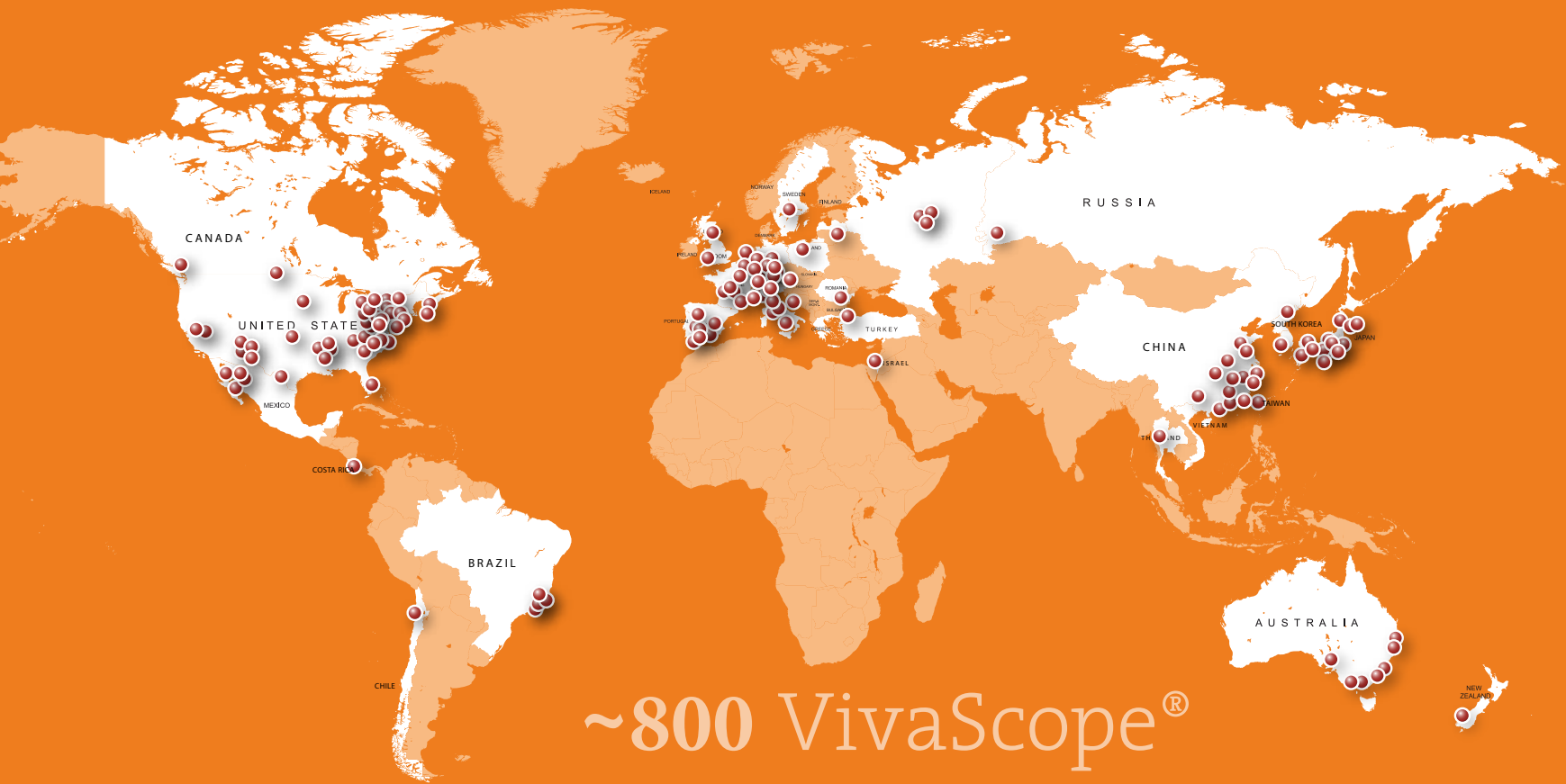
Confocal Laser Scanning Microscopy – In Vivo Histology for Cellular Level Skin Analyses in Cosmetic Research and Dermopharmacy



Pigmentation and Whitening  
Aging  
Inflammatory Cutaneous Status  
Aesthetic Dermatology  
Wound Healing and Scars  
Penetration  
Antiperspirants  
Hair Disorders  
Adnexal Structure Involvement  
*Fluorescence*

A  
Window  
into the  
Skin.





~800 VivaScope®



### Tradition and Innovation

Mavig GmbH, a family owned and operated company founded in 1921 and headquartered in Munich, is a quality and innovation leader in the field of X-ray protection. Lucid, Inc., operating as Caliber Imaging & Diagnostics Inc., based in Rochester, New York (USA), is producer of the VivaScope product range. In 2006 VivaScope assumed the confocal laser technology distribution rights for Europe, Russia, the Middle East, and North Africa. Both companies work hand in hand concerning R&D in the field of laser scanning microscopy.

*The VivaScope product series is successfully used in Europe, as well as internationally.*

# Competitive Edge in Research and Competency.

## Optical Skin Biopsy in Real-Time

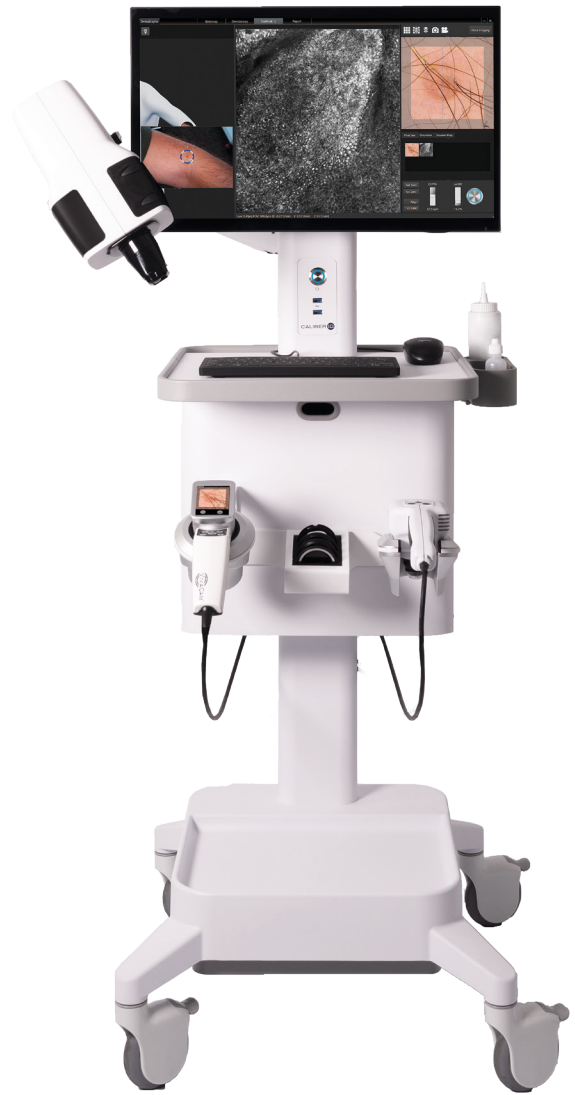Confocal laser scanning microscopy opens a “window into the skin”. This innovative imaging process provides for the first time a non-invasive view into the epidermis and superficial dermis – in a pain free, uncomplicated, and quick manner.

## Leading in Service and Consultation

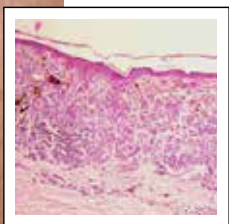
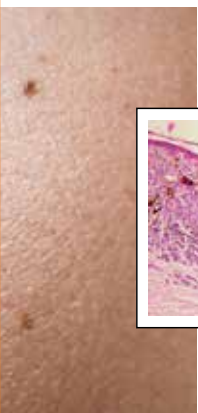
MAVIG's product portfolio not only includes devices and software for confocal laser scanning microscopy – in vivo and ex vivo. The company also provides comprehensive workshops and training opportunities using the actual devices as well as training materials for independent study. Users are able to expand and improve their application skills during a supervised online training session.

## Microscopically Accurate and Non-Invasive

Confocal laser scanning microscopes offered by VivaScope make it possible to depict different skin structures step by step horizontally with microscopic accuracy and in cellular resolution.

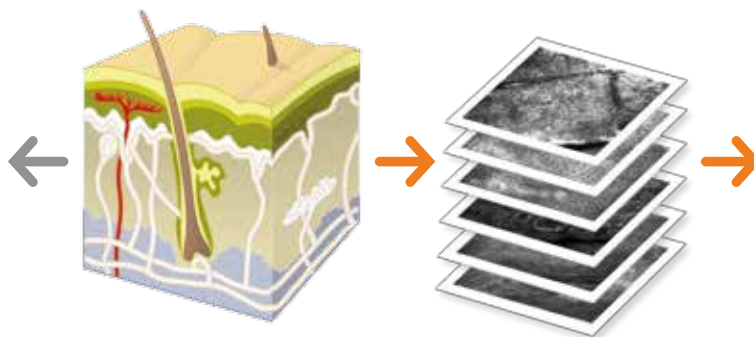


*VivaScope offers different confocal laser scanning microscopes for in vivo use – on living tissue – as well as the associated imaging software.*



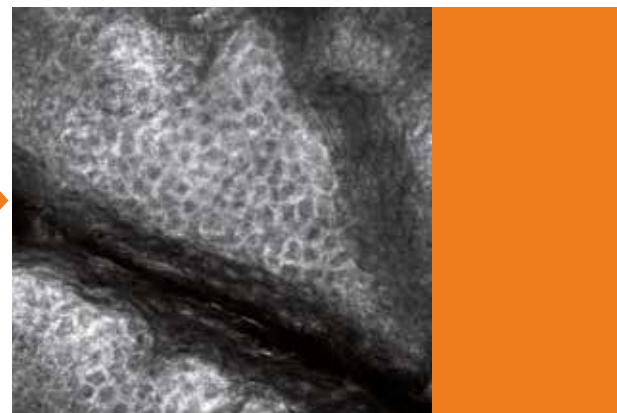
© Prof. J. Welzel,  
Klinikum Augsburg,  
Germany

H&E section



Skin model

Optical cross section of single skin layers from the surface down into the deepness of the skin.



## What is Confocal Laser Scanning Microscopy?

Confocal laser scanning microscopy makes it possible to depict cellular structures of living tissue in real-time and without the need for complex and lengthy preparation protocols and without invasive biopsies. The same area with a dimension of up to 8 x 8 mm can be repeatedly scanned and examined at different times. This method allows cosmetic research to document skin changes precisely, quickly and non-invasively and to analyze modes of action and the effectiveness of cosmetic and pharmacological substances and ingredients. New applications in the field of aesthetic and dermatological research are added all the time.

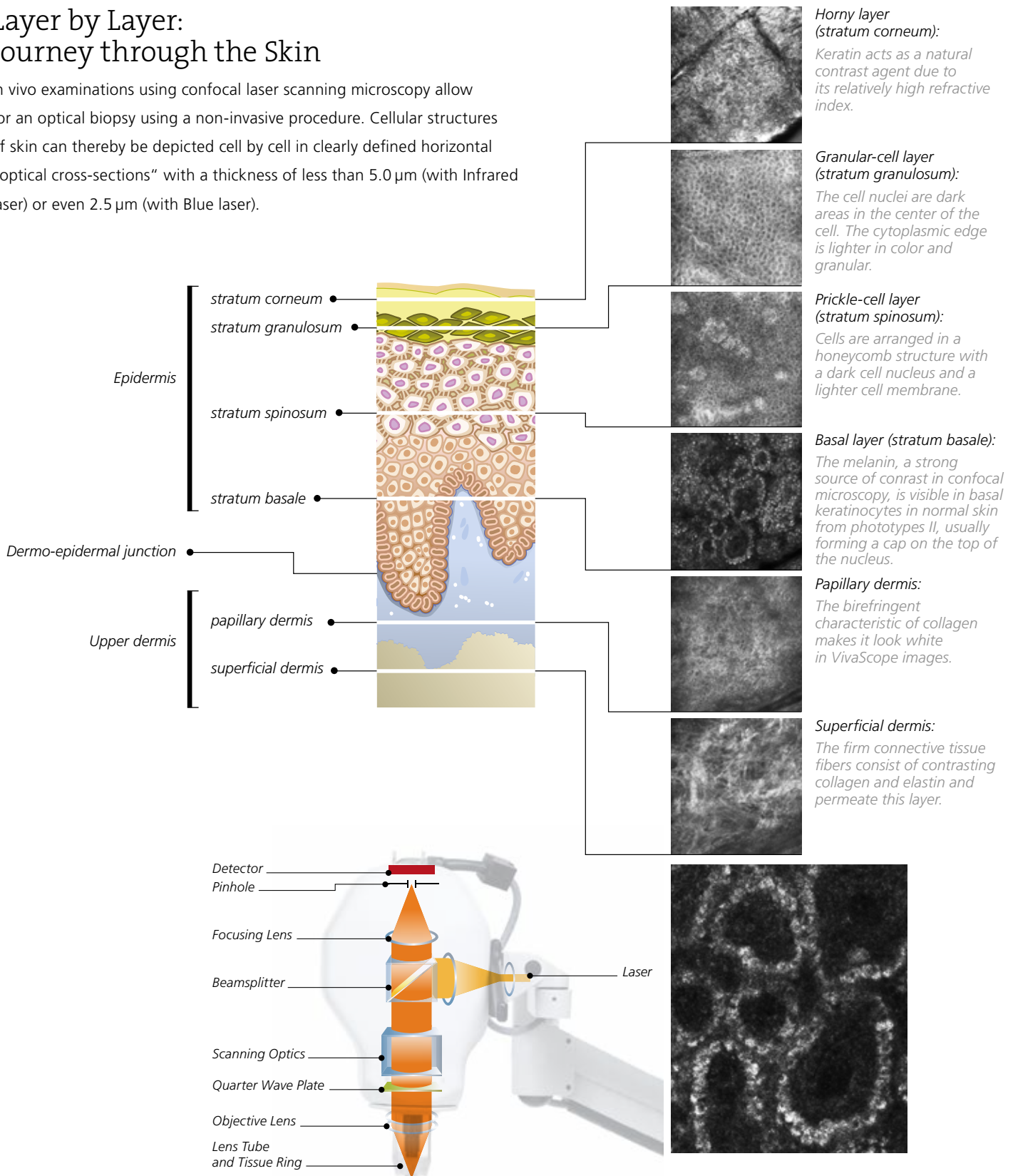


# A Window into the Skin.

## Layer by Layer: Journey through the Skin

In vivo examinations using confocal laser scanning microscopy allow for an optical biopsy using a non-invasive procedure. Cellular structures of skin can thereby be depicted cell by cell in clearly defined horizontal „optical cross-sections“ with a thickness of less than 5.0  $\mu\text{m}$  (with Infrared laser) or even 2.5  $\mu\text{m}$  (with Blue laser).

Normal, untreated skin during a confocal in vivo scanning. Field of view 500  $\mu\text{m}$  x 500  $\mu\text{m}$ .



To generate confocal images, a laser beam is directed through a beam splitter and an interconnected lens system and scanned into the skin to be examined, from where it is then reflected by the different components of the tissue. The confocal arrangement of the detector aperture makes it possible to detect only the in-focus light which is reflected from the skin, rejecting out-of-focus light to improve resolution and contrast within the specimen.

# Cosmetic Research – Generating Precise Tissue Analyses Surprisingly Fast and Easily

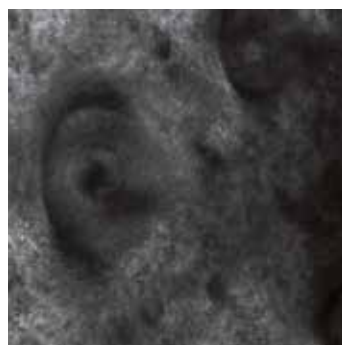
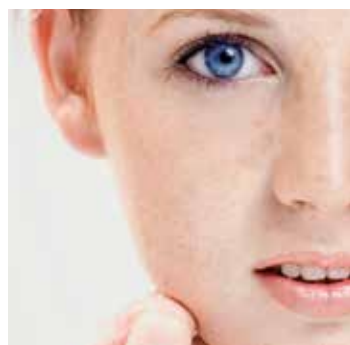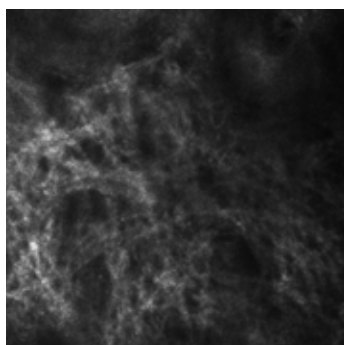
## What are the applications of confocal laser scanning microscopy?

VivaScopes are used in medical fields and applications as well as cosmetic and Pharma research. Numerous companies from the cosmetics industry have been working with VivaScope devices for many years. Manufacturers and research companies such as Ashland, Beiersdorf and proDERM use the confocal laser scanning microscope, for example, for scientific studies and claims validation. The effectiveness of topical substances on the different skin compartment (different epidermal layers and papillary dermis) can be checked in vivo without subjecting test persons to a skin biopsy. The focus of the basic research is here on the guaranteed effectiveness and compatibility of newly developed

skin and hair care products and on the prevention and remedy of skin damages. For example, some of the applications include pigmentation, skin aging, and measuring the epidermal thickness, sun damage, hydration, penetration, inflammatory diseases such as psoriasis or lupus, contact and irritant dermatitis, hair, as well as wound and scar healing. Aesthetic treatments such as peeling and laser treatments can also be monitored with confocal images, as well as the effects of antiperspirants and the skin changes brought about by acne or rosacea. Additional therapeutic indications are added over time.

### Skin Aging

A VivaScope examination clearly depicts changes in the collagen fibers of the skin due to aging.



Face (cheek) of a 22-year-old person in confocal image

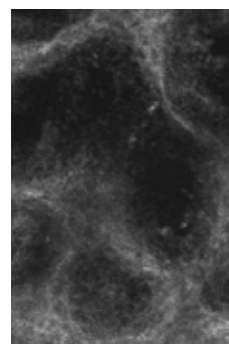
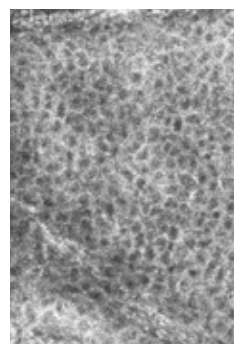
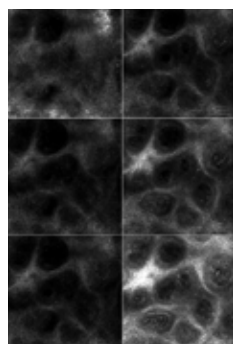
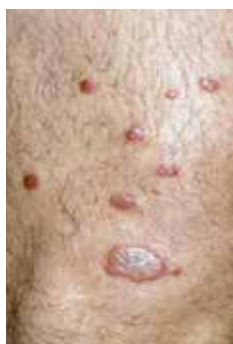Confocal image of the same skin area of a 71-year-old woman

© D. Hottelart, K. Vié – Laboratoires Clarins, France

### Psoriasis

Confocal laser scanning microscopy also facilitates differential diagnosis in case of psoriasis.

The confocal image depicts round to polygonal, highly refractile cells, especially in the stratum spinosum.



Clinical image shows erythematous, scaling papules and patches (43 year old man).

Confocal microscopy shows the presence of bright structures in the stratum corneum corresponding to parakeratosis ...

... thickened stratum corneum and epidermis (evaluated using vertical VivaStack software registration) ...

... numerous non-edged papillae containing highly refractile round to oval structures (orange asterisks) representing inflammatory blood cells at the dermo-epidermal junction ...

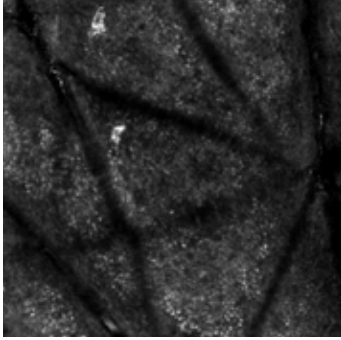
... normal honey-comb pattern in the epidermis.

At the level of the upper dermis the dermal papillae are enlarged with thin interpapillary rete ridges and filled up with dilated blood vessels. Inflammatory cells are visible around blood vessels.

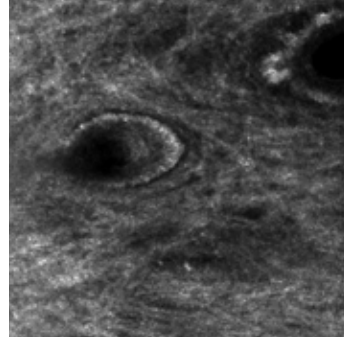
© Dr. M. Ardigò, San Gallicano Dermatological Institute, Rome, Italy

## Melasma

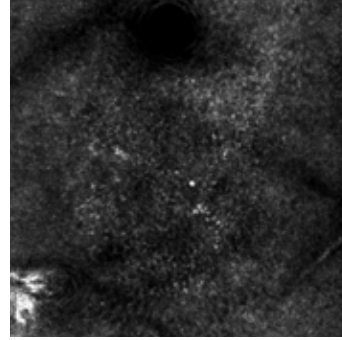
Confocal images show the increased presence of pigmented keratinocytes and melanophages in the dermis in case of hyperpigmentation (melasma lesions). Confocal microscopy is able to follow up the treatment disclosing the reduction of pigmented keratinocytes in the epidermis and at the dermo-epidermal junction as well as the melanophages in the dermis. **Melasma lesion on the face (cheeks) of a phototype III, 39-year-old woman.**



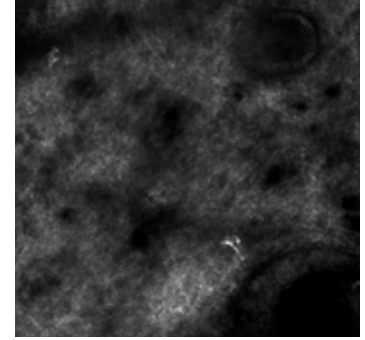
Presence of pigmented keratinocytes at the level of the stratum spinosum ...



... and both at the level of dermo-epidermal junction (corresponding to epithelial adnexal structures and in the dermis as melanophages, seen as polygonal, mildly bright structures between collagen bundles.



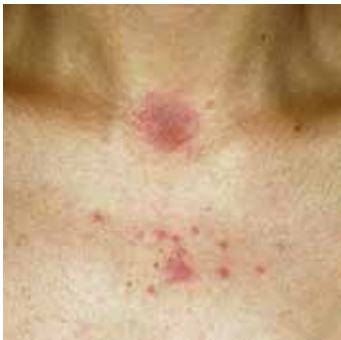After 2 months of hydroquinone daily applications, partial disappearance of pigmented keratinocytes ...



... and no pigmentation at the level of the upper dermis and of epithelial adnexal structures.

## Lupus

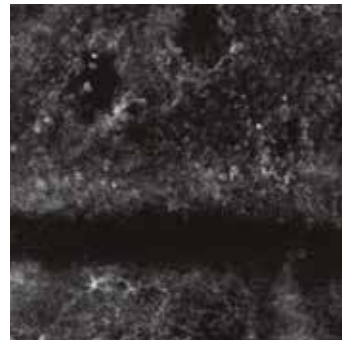
Confocal images show lupus as a change in the dermoepidermal junction zone, among others. Papillary rims become fuzzy due to the accumulation of inflammatory cells.



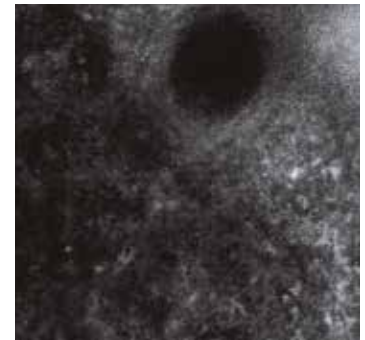
Erythematous violaceous plaques located at the level of the upper trunk of a 32-year-old woman.



Confocal image taken at the level of the epidermis discloses the presence of sparse, mildly refractile cellular structures, corresponding to exocytosis of inflammatory cells with disarray of the epidermis.



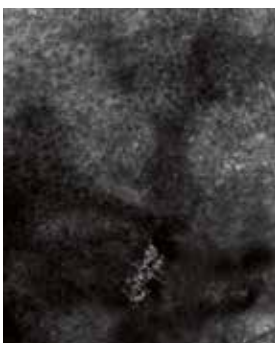At the level of the dermoepidermal junction, the papillary rims are obscured by the presence of numerous inflammatory cells ...



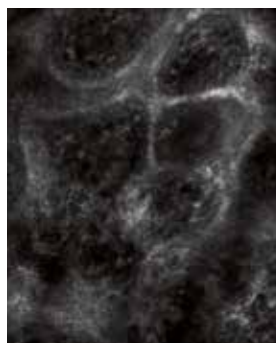
... which are also visible in the upper dermis with an adnexocentric tendency.

## Vitiligo

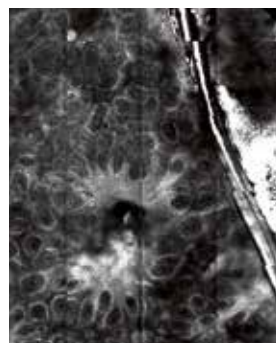
In case of vitiligo, confocal laser scanning microscopy is used to portray the reduction or lack of melanocytes, which produce melanin or pigmented keratinocytes in the dermoepidermal junction zone. **Vitiligo affecting a phototype III patient:**



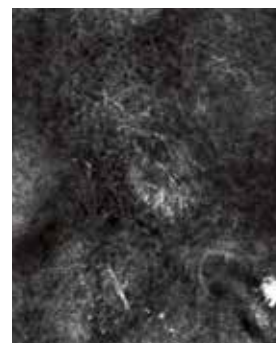
RCM of vitiligo lesion shows absence of pigmentation of keratinocytes ...



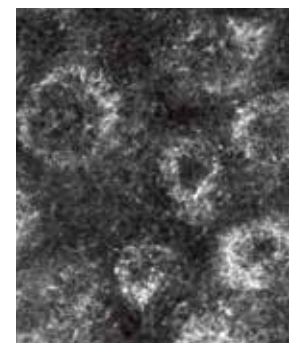
... and disappearing of the bright rim around the dermal papillae.



After 2 months of UVB treatment (3 times a week), RCM examination discloses the presence of highly reflecting areas at mosaic ...



... and presence of dendritic cells above ...

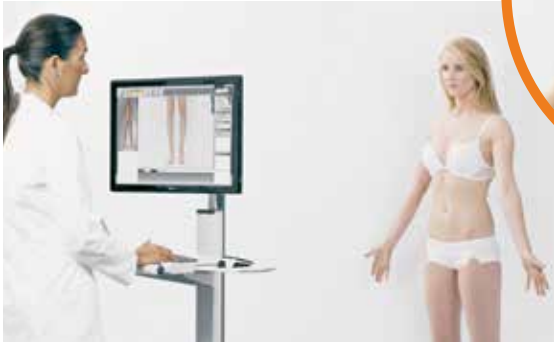

... as well as at the level of the dermo-epidermal junction, where basal keratinocytes become clearly detectable for the accumulation of melanin.

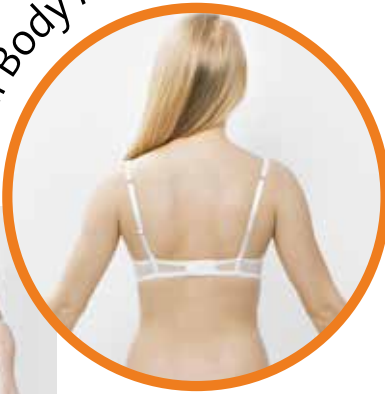

# Simple and Highly Detailed – the Entire Imaging Chain. Documentation and Analysis with the VivaScope.

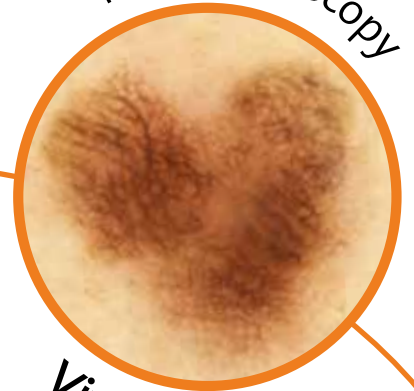The examination process and documentation are managed with the use of one software surface only. Due to the integration of total body mapping, clinical imaging with dermoscopy and confocal microscopy, a quick and smooth dermatological examination process is possible.



Total Body Mapping

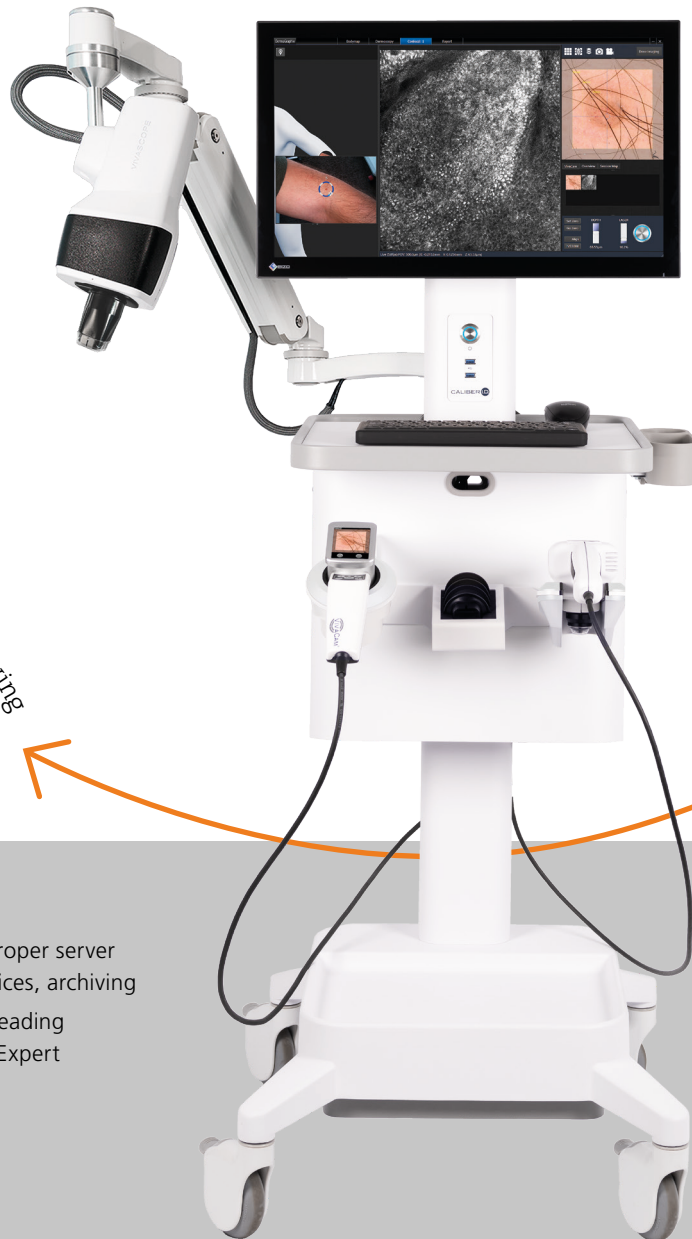


HD-Dermoscopy

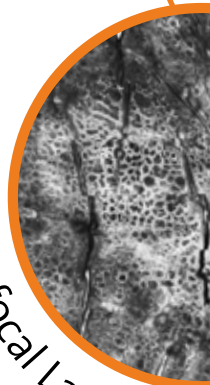


VivaCam®

Standardized  
Total Body  
Mapping  
Documentation



Confocal Laser



Internal Diagnosis & Archiving

VivaLAN

External Diagnosis & Archiving

VivaNet®



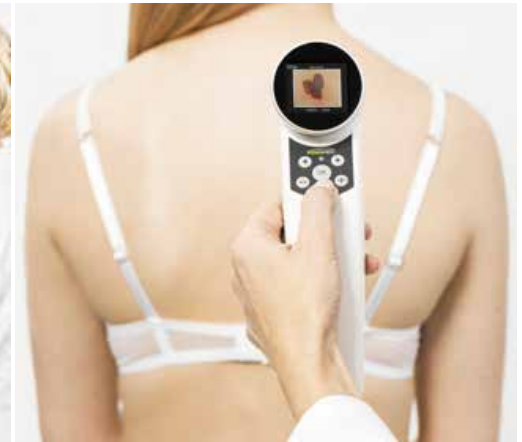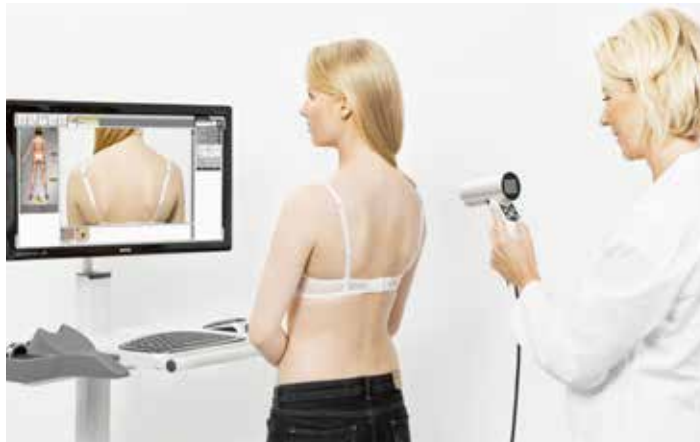- Networking of the proper server and the imaging devices, archiving
- Direct diagnosis on reading workstations by the Expert

- Teledermatology Service with external VivaNet Server for encrypted storage, retrieval and transfer of patient data
- prompt assessment by specialists (external)



## Imaging of clinical and dermoscopic features

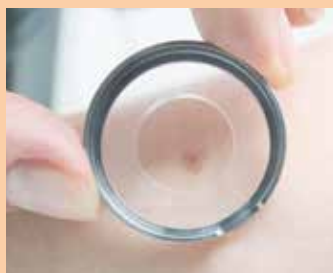is possible with one device only, the VivaCam.



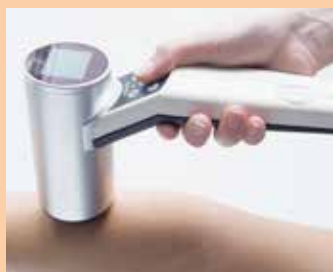## Quick and easy: the confocal examination.

All confocal laser scanning microscopes are developed and produced specifically for daily practical use. Within the scope of their intended usage, they are robust devices suitable for a variety of applications. Confocal images can be generated and analyzed in just a few steps.

### Examination process:



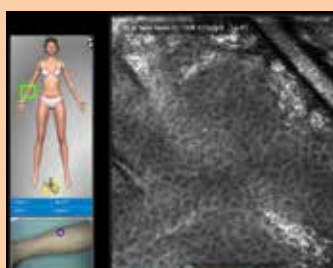
*The tissue window is placed onto the skin and is used as an adapter for VivaCam and VivaScope in order to provide a correlation between the dermoscopic and confocal image.*



*The dermoscopic image is taken with the VivaCam and may be used to navigate the laser in the lesion.*



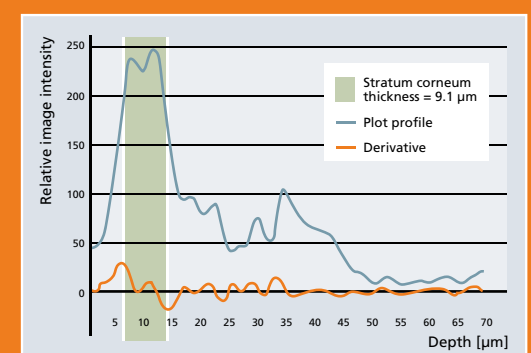
*The laser tube of the VivaScope 1500 is affixed to the tissue ring.*



*Different sets of confocal images can be acquired as desired.*

## Availability of specific analysis tools (i. e. ConfoScan) adapted to skin changes:

- High-intensity Objects / Adaptive Elliptic Model Analysis
- Dark Objects / Adaptive Elliptic Model Analysis
- High-intensity Objects / Fixed Circular Model Analysis
- Dark Objects / Fixed Circular Model Analysis
- Texture Analysis
- Vertical Reconstructions / Dimensional measurements
- 3D-Visualization

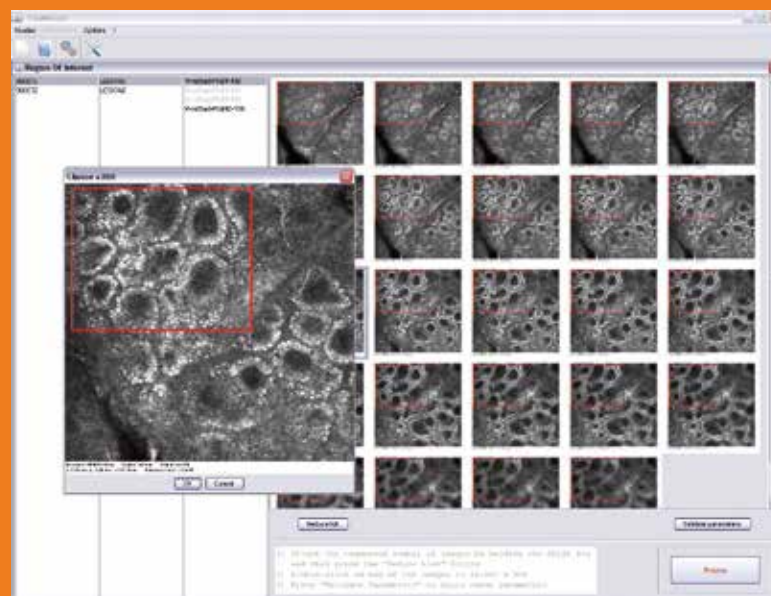


*Subsequent analysis of the image data with various software such as ConfoScan or Image J*

VivaScope®  
Microscopy

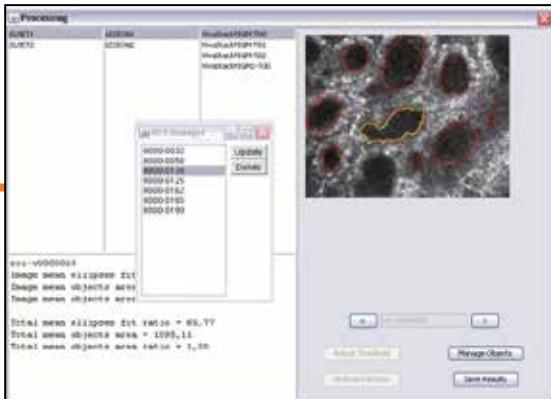
# Quantification and Analysis of Confocal Images with ConfoScan

The skin structures and tissue changes depicted in the confocal images can be analyzed, quantified, and further processed with **ConfoScan software** (OrionTechnoSoft). This software program especially designed for VivaScope products is well-suited for the researching cosmetics industry – and is continuously optimized to meet the specific needs of these types of organizations. The capabilities of the qualification software developed by Jean Christophe Pittet from ORION Concept (Tours, France) includes measuring the thickness of the stratum corneum, quantifying melanin, as well as recording size, shape, and number of different skin cells and dermal papillae. Quantitative and qualitative image processing makes it possible to analyze color nuances and shapes precisely.

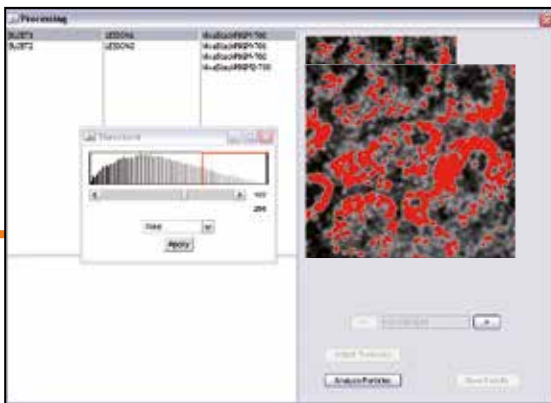


*After a VivaStack (here) or VivaBlock image acquisition has been generated, the confocal images can be exported to the software for further image processing.*

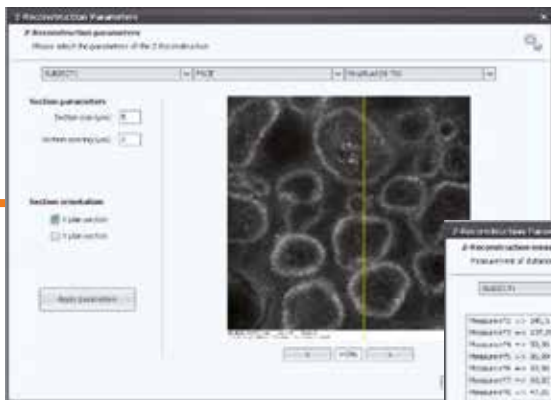
*In the main window, the selection of images (continuous or non-continuous) of a VivaStack or VivaBlock is presented. In the pop-up window, the region of interest can be selected and is applied to the whole selection.*



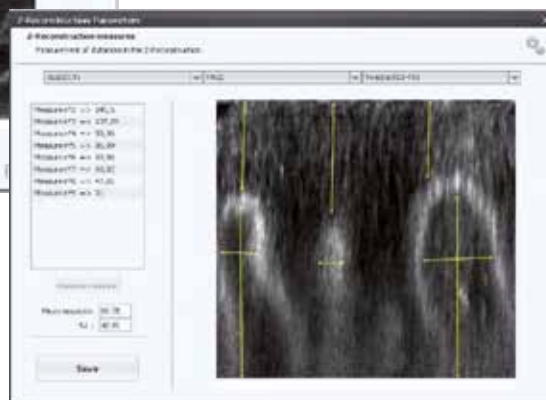Automatic papillae detection for the selected region of interest with either the elliptic model (red lines) or a finer contour determination (yellow line). The geometrical properties of the contours are registered.



Example of analysis: pigmentation detection related to the basal cells on the entire selected image corresponding to the basal layer.

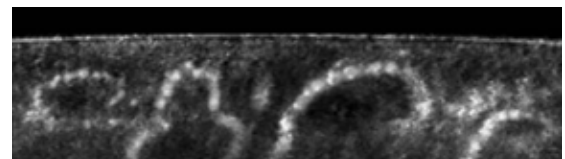


Vertical image reconstruction: In one of the images, the plane for the vertical reconstruction is selected (yellow line = resection of the whole VivaStack in z direction).



On the reconstructed image, it is possible to measure and quantify different properties (e.g. dimensions of papillae, thickness of layers, distances).

Enhanced reconstructed vertical image in real size (500 x 150  $\mu\text{m}$ , from the stratum corneum to the papillary dermis).

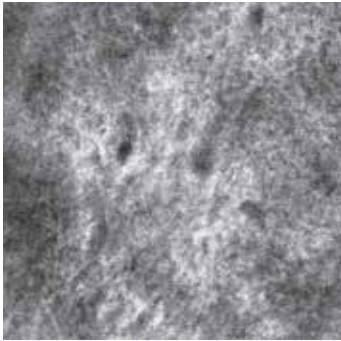




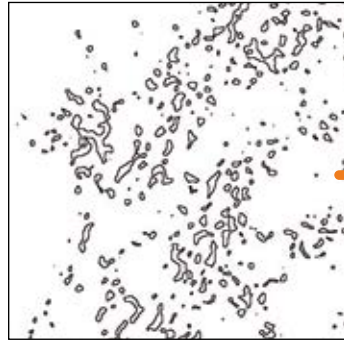
# Examples for the Treatment with Cosmetic Products

## Anti-aging effect down to the superficial dermis

Before treatment




Superficial dermis before treatment, confocal image 500 x 500 μm

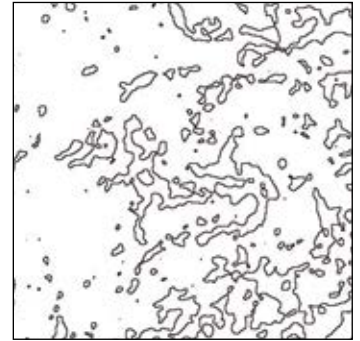


Texture of superficial dermis, processed with ConfoScan

After treatment

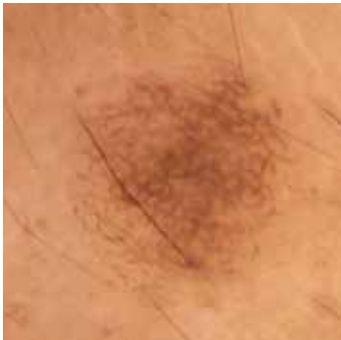

Superficial dermis after 56 days of treatment; confocal image 500 x 500 μm




Texture of superficial dermis, processed with ConfoScan

## Decrease of Cutaneous Pigmentation Spots

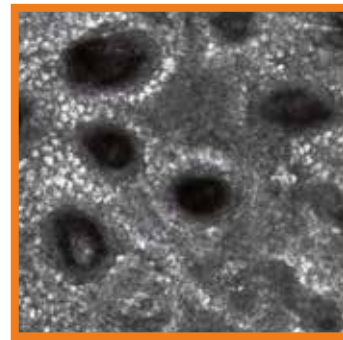


Macroscopic image with VivaCam® of pigmented spot 10 x 10 mm



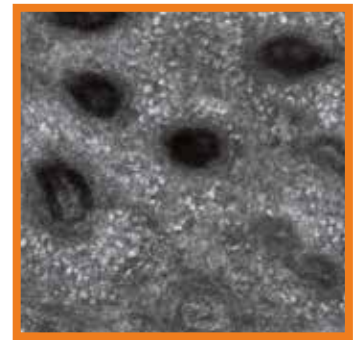
VivaBlock® 5 x 5 mm of the same spot

Before treatment



Pigmentation before treatment, confocal image 500 x 500 μm

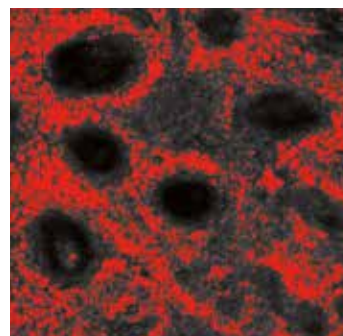
After treatment



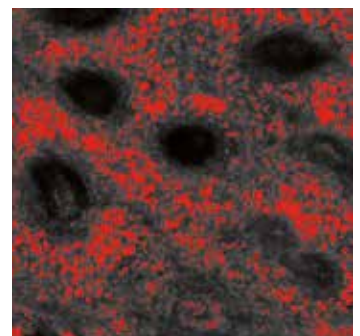
Pigmentation after 56 days of treatment, confocal image 500 x 500 μm of the same area

Study Name	Study Parameters	Study Analysis Type	Mean Cells/Spot	Mean Image Area	Mean Cells/Image Area	Mean Number of Cells
8	PIGMENTATION	PIGMENTATION	2043.0	8870.0	46.8	1170.0
9	PIGMENTATION	PIGMENTATION	1974.0	5281.0	46.8	1015.0
10	PIGMENTATION	PIGMENTATION	1852.0	3987.0	46.7	1014.0
11	PIGMENTATION	PIGMENTATION	1648.0	7049.0	46.7	1784.0
12	PIGMENTATION	PIGMENTATION	1198.0	4543.0	41.1	1144.0
13	PIGMENTATION	PIGMENTATION	1867.0	14189.0	46.1	1074.0

For both analysis, melanin detection is obtained by automatic analysis of a series of images corresponding to the whole basal layer. All results are collected in an Excel file so that the decrease of pigmentation can be quantified (mean and total values of cells containing melanin).



Detection of melanin before treatment, processed with ConfoScan




Detection of melanin after 56 days of treatment, processed with ConfoScan



# Analysis of the Confocal Images with ImageJ

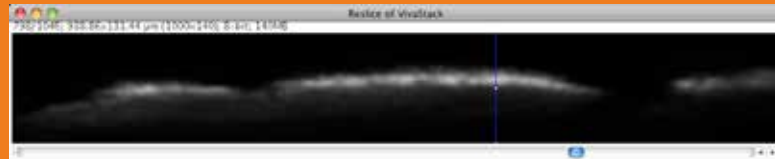The software **Image J**, available for free (<http://rsb.info.nih.gov/ij/>) represents another option for analyzing confocal images, for example, in the areas of measuring thicknesses or to analyze the property and architecture of skin folds or wrinkles. ImageJ is a Java image-processing program also suitable for editing and analyzing the confocal images. The image contrast can be adjusted, soft-focus and sharpening of the images are possible as well as the simultaneous processing of several images in only one run.



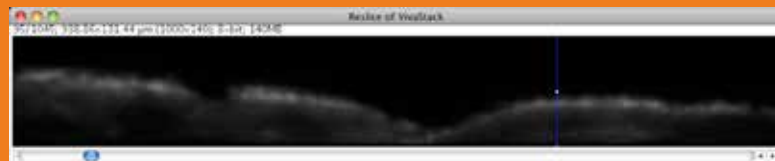
VivaStack, scanned with constant laser power

## Vertical reconstruction

from a VivaStack (one scanning point) with 140 images (layer intervals of 0.94  $\mu\text{m}$ ) and blue plot line for measuring the stratum corneum (SC) thickness.



Reconstructed image before tape stripping. The white layer of the stratum corneum is clearly visible. The determined SC thickness is 12.02  $\mu\text{m}$ .



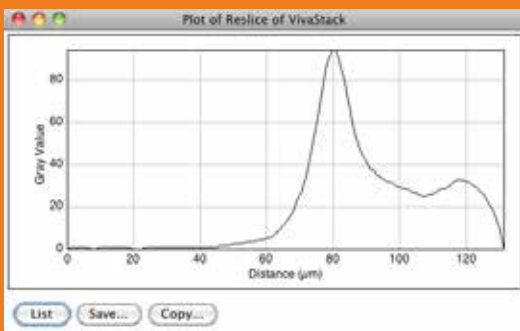
Reconstructed image after tape stripping. The reduction of the stratum corneum by 30% to a thickness of 8.45  $\mu\text{m}$  is clearly visible.



## Analysis

After selecting a suitable measurement point, entering the scale, and smoothing the image to avoid motion artifacts, a vertical line is plotted. The intensity of reflection can be defined along this line graphically and in tabular form.

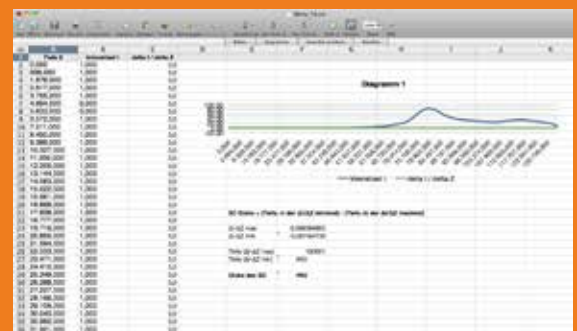
The measured values are analyzed after the tape stripping.



Graphical depiction of the intensity across the depth (blue plot line in the two images above). The peak represents the heavily reflecting layer of the SC, high in keratin content. The thickness can be determined from the distance of the turning point of the peak or the max. and min. of the first derivative.

X	Y
69.475	24
70.414	27
71.353	32
72.292	37
73.231	44
74.170	51
75.109	60
76.047	68
76.986	77
77.925	85
78.864	91
79.803	94
80.742	94
81.681	92
82.620	86
83.558	79
84.497	71
85.436	64

Tabular depiction of the intensity values for the precise calculation of the SC thickness using a spreadsheet analysis.



The SC thickness is determined from the absolute values of the distance between the max. and min. of the first derivative of the intensity curve with the help of a spreadsheet analysis

# Confocal Microscopy: Recognized for Research and Practical Application.

## References

More than 550 publications in medical journals as well as feature articles testify to the diverse application possibilities of the VivaScope devices. The number of recognized indications is continuously increasing with the associated studies usually determining a very high sensitivity and specificity.

## Confocal Microscopy

Fundamentals, Reviews and Perspectives. The „Online Collection Booklet“ gives you an excellent overview about all studies  
[www.vivascope-pub.com](http://www.vivascope-pub.com)

**New: Online Collection Booklet**  
**Confocal Microscopy**  
Fundamentals, Reviews and Perspectives >>> [www.vivascope-pub.com](http://www.vivascope-pub.com)

**Online Collection Booklet**  
**Confocal Microscopy**  
Fundamentals, Reviews and Perspectives  
> 537 Publications for Medical and  
Cosmetic Research for in vivo and ex vivo  
[www.vivascope-pub.com](http://www.vivascope-pub.com)

## Selection of Relevant Studies for Cosmetic Research

### ■ Skin Aging, Sun Damage and Epidermis Thickness

- [1] Haytuglu NS, Gurel MS, Erdemir A, Falay T, Dolgun A, Haytuglu TG.: „Assessment of skin photoaging with reflectance confocal microscopy.“ *Skin Res Technol.* 2014 Aug; 20(3):363-72. Doi: 10.1111/srt.12127.
- [2] Longo C, Casari A, Beretti F, Cesinaro AM, Pellacani G: *Skin aging: in vivo microscopic assessment of epidermal and dermal changes by means of confocal microscopy.* *J Am Acad Dermatol.* 2013 Mar;68(3):e73-82. Doi: 10.1016/j.jaad.2011.08.021.
- [3] Longo C, Galimberti M, De Pace B, Pellacani G, Bencini PL.: „Laser skin rejuvenation: epidermal changes and collagen remodeling evaluated by in vivo confocal microscopy.“ *Lasers Med Sci.* 2013 May;28(3):769-76. Doi: 10.1007/s10103-012-1145-9.
- [4] Koller S, Inzinger M, Rothmund M, Ahlgrimm-Siess V, Massone C, Arzberger E, Wolf P, Hofmann-Wellenhof R.: „UV-induced alterations of the skin evaluated over time by reflectance confocal microscopy.“ *J Eur Acad Dermatol Venereol.* 2013 Oct 17. Doi: 10.1111/jdv.12284.
- [5] Smiltneek A, Hoffman D, Basehoar A, Stabe L, Nussbaum C, Reece B, Cunningham C, Koenig D: „Comparison of Stratum Corneum Thickness Calculated from in vivo Raman Spectroscopy and Confocal Imaging.“ Poster presented at ISBS 2009.

### ■ Pigmentation and Vitiligo

- [1] Longo C, Pellacani G, Tourlaki A, Galimberti M, Bencini PL: „Melasma and low-energy Q-switched laser: treatment assessment by means of in vivo confocal microscopy.“ *Lasers Med Sci.* 2014 May;29(3):1159-63. Doi: 10.1007/s10103-013-1498-8.
- [2] Costa MC, Eljaiek HV, Abraham LS, Azulay-Abulafia L, Ardigó M.: „In vivo reflectance confocal microscopy in a typical case of melasma.“ *An Bras Dermatol.* 2012 Sep-Oct;87(5):782-4.
- [3] Kang HY, Bahadoran P, Suzuki I, Zugaj D, Khemis A, Passeron T, Andres P, Ortonne JP.: „In vivo reflectance confocal microscopy detects pigmentary changes in melasma at a cellular level resolution.“ *Exp Dermatol* 2010; 19(8):e228-33. Doi: 10.1111/j.1600-0625.2009.01057.x.
- [4] Xiang W, Xu A, Bi Z, Shang Y, Ren Q.: „In vivo confocal laser scanning microscopy of hypopigmented macules: a preliminary comparison of confocal images in vitiligo, nevus depigmentosus and postinflammatory hypopigmentation.“ *Lasers Med Sci.* 2010;25(4):551-8. Doi: 10.107/s10103-010-0764-2.

## ■ Inflammatory Diseases

- [1] Wolberink EA, van Erp PE, de Boer-van Huizen RT, van de Kerkhof PC, Gerritsen MJ.: „**Reflectance confocal microscopy: an effective tool for monitoring ultraviolet B phototherapy in psoriasis.**” *Br J Dermatol.* 2012 Aug;167(2):396-403. Doi: 10.1111/j.1365-2133.2012.10988.x.
- [2] Wolberink EA, van Erp PE, Teussink MM, van de Kerkhof PC, Gerritsen MJ.: „**Cellular features of psoriatic skin: imaging and quantification using in vivo reflectance confocal microscopy.**” *Cytometry B Clin Cytom.* 2011 May;80(3):141-9. Doi: 10.1002/cyto.b.20575.
- [3] Debarbieux S, Depaepae L, Poulalhorn N, Dalle S, Balme B, Thomas L.: „**Reflectance confocal microscopy characteristics of eight cases of pustular eruptions eruptions and histopathological correlations.**” *Skin Res Technol.* 2013 Feb;19(1):e444-52. Doi: 10.1111/j.1600-0846-2012.00662.x.

## ■ Dermatitis

- [1] Astner S, Burnett N, Rius-Díaz F, Doukas AG, González S, González E.: „**Irritant Contact Dermatitis Induced by a Common Household Irritant: A Noninvasive Evaluation of Ethnic Variability in Skin Response.**” *J Am Acad Dermatol.* Mar 2006; 54(3):458-65.
- [2] Astner S, González E, Cheung A, Rius-Díaz F, González S.: „**Pilot Study on the Sensitivity and Specificity of In Vivo Reflectance Confocal Microscopy in the Diagnosis of Allergic Contact Dermatitis.**” *J Am Acad Dermatol.* Dec 2005; 53(6):986-92.
- [3] Astner S, González E, Cheung A, Rius-Díaz F, Doukas A, William F, González S.: „**Non-invasive Evaluation of the Kinetics of Allergic and Irritant Contact Dermatitis.**” *J Invest Dermatol.* Feb 2005; 124(2): 351-9. Doi 10.1111/j.0022-202X.2004.23605.x.

## ■ Wound and Scar Healing

- [1] Sattler EC, Poloczek K, Kästle R, Welzel J.: „**Confocal laser scanning microscopy and optical coherence tomography for the evaluation of the kinetics and quantification of wound healing after fractional laser therapy.**” *J Am Acad Dermatol.* 2013 Oct;69(4):e165-73. Doi: 10.1016/j.jaad.2013.04.052.
- [2] Lange-Asschenfeldt S, Bob A, Terhorst D, Ulrich M, Fluhr J, Mendez G, Roewert-Hubert HJ, Stockfleth E, Lange-Asschenfeldt B.: „**Applicability of confocal laser scanning microscopy for evaluation and monitoring of cutaneous wound healing.**” *J Biomed Opt.* 2012 Jul; 17(7):076016. Doi: 10.1117/1.JBO.17.7.076016.
- [3] Altintas AA, Guggenheim M, Altintas MA, Amini P, Stasch T, Spilker G.: „**To heal or not to heal: predictive value of in vivo reflectance-mode confocal microscopy in assessing healing course of human burn wounds.**” *J Burn Care Res.* 2009 Nov-Dec; 30(6):1007-12. Doi: 10.1097/BCR.0b013e3181bfb810.

- [4] Altintas AA, Altintas MA, Ipaktchi K, Guggenheim M, Theodorou P, Amini P, Spilker G.: „**Assessment of microcirculatory influence on cellular morphology in human burn wound healing using reflectance-mode-confocal microscopy.**” *Wound Rep Reg.* 2009 Doi: 10.1111/j.1524-475X.2009.00516.x.

## ■ Hair Loss

- [1] Ardigó ;. Tosti A, Cameli N, Vincenzi C, Misciali C, Berardesca E.: „**Reflectance confocal microscopy of the yellow dot pattern in alopecia areata.**” *Arch Dermatol.* 2011 Jan;147(1):61-4. Doi: 10.1001/archdermatol.2010.288.
- [2] Rudnicka L, Olszewska M, Rakowska A.: „**In vivo reflectance confocal microscopy: usefulness for diagnosing hair diseases.**” *J Dermatol Case Rep* 2008; 4: 55-59. Doi: 10.3315/jdc.2008.1017.
- [3] Fox CA, Koon DC, Eastman JM.: „**Confocal Imaging of Human Hair for Cosmetic Application.**” Poster Presentation. TRI Princeton Hair Research Conference. 2004.

## ■ Laser Treatments

- [1] Longo C, Galimberti M, De Pace B, Pellacani G, Bencini PL.: „**Laser skin rejuvenation: epidermal changes and collagen remodeling evaluated by in vivo confocal microscopy.**” *Lasers Med Sci.* 2013 May;28(3):769-76. Doi: 10.1007/s10103-012-1145-9.
- [2] Erdoğan S, Dorittke P, Kardorff B.: „**Pulsed dye laser (FPDL) treatment of a plantar verruca vulgaris and in vivo monitoring of therapy with confocal laser scan microscopy (CLSM).**” *J Dtsch Dermatol Ges.* 2013 Aug;11(8):760-2. Doi: 10.1111/ddg.12110.

## ■ Strip Patch Test

- [1] Dickel H, Goulioumis A, Gambichler T, Fluhr JW, Kamphowe J, Altmeyer P, Kuss O.: „**Standardized tape stripping – A practical and reproducible protocol to reduce uniformly the stratum corneum.**” *Skin Pharmacol Physiol.* 2010;23(5):259-65. Doi: 10.1159/000314700.


## ■ Additional Studies

- [1] Manfredini M, Mazzaglia G, Ciardo S, Simonazzi S, Farnetani F, Longo C, Pellacani G.: „**Does skin hydration influence keratinocyte biology? In vivo evaluation of microscopic skin changes induced by moisturizers by means of Reflectance Confocal Microscopy.**” *Skin Res Technol.* 2013 Feb 26. Doi: 10.1111/srt.12042.
- [2] Sattler E, Kästle R, Arens-Corell M, Welzel J.: „**How long does protection last?--in vivo fluorescence confocal laser scanning imaging for the evaluation of the kinetics of a topically applied lotion in an everyday setting.**” *Skin Res Technol.* 2012 Aug;18(3):370-7. Doi: 10.1111/j.1600-0846.2011.00579.x.



## Learning from the Best.

Service and Support from the Start. With the help of the free training options offered by VivaScope, handling and use of the VivaScope devices is quickly and easily learned. An ingenious and comprehensive confocal laser scanning microscopy **training program** creates the optimal prerequisites for analyzing and diagnosing confocal images quickly and – most importantly – reliably.





The training program consists of several consecutive training modules:



## 1. Introductory Training On-Site

Training lasting one to two days offered, after the installation of the device, and provides dermatologists or pathologists with basic knowledge and skills necessary to start using VivaScope devices without further delay. Presentations, manuals, imaging guidelines, and studies provide additional support and assistance.

## 2. Independent study with textbook

The image textbook prepared by four leading experts in the field of confocal laser scanning microscopy is especially well suited for the independent study of image interpretation. This hands-on guide is generously illustrated with numerous confocal images. It provides schematic drawings of the tumor criteria and a chapter specifically devoted to bridging the gap between dermoscopy, RCM, and histopathology.

## 3. Expert Training

Advanced VivaScope users have the opportunity to expand and solidify their knowledge of the many different confocal laser scanning microscopy options in a clinical setting.

At the **Sapienza Università di Roma**, VivaScope users can attend an advanced training on the diagnosis of **pigmented lesions and non-pigmented lesions**, inflammatory skin diseases, and cosmetology. The training is held by Prof. Giovanni Pellacani in collaboration with Dr. Marco Ardigo (Rome), Dr. Caterina Longo (Reggio Emilia) and Dr. Martina Ulrich (Berlin).

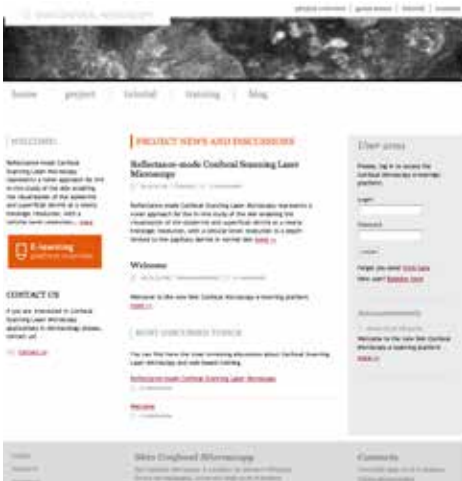
At the **University of Barcelona (Hospital Clínic)**, users of Ex-Vivo as well as those interested can deepen their knowledge. The training will be organized by Dr. Susana Puig, Dr. Josep Malvehy and Dr. Toni Benassar.



**SAPIENZA**  
UNIVERSITÀ DI ROMA



**Universitat de Barcelona**



## 4. Online Training

Within the scope of intensive continuous training, VivaScope users are able to review numerous sample cases posted at **www.vivascope-academy.com**. This expert training was devised by Prof. Giovanni Pellacani and consists of levels that build on one another. The foundation courses of the **University of Rome** are the basis for this online training.

## 5. Online Expert Tutorial

For difficult cases, VivaScope users can get a "second opinion" from confocal experts with years of experience. This training module will allow readers of confocal images to expand their own expertise and increase their ability to diagnose even problematic lesions with a high degree of reliability and accuracy. The Online Expert Tutorial is not intended as clinical second opinion for any case, but rather as an educational tool.



## Independent International Circle of Experts

The **International Confocal Group (ICG)** has been meeting regularly since the beginning of 2008. More than 200 physicians of different disciplines ensure the interdisciplinary information exchange is lively and valuable. Establishing confocal laser scanning microscopy as the standard in dermatological diagnosis and the expansion of the range of medical indications and uses are the goal of the ICG. National and international interested VivaScope users can join the ICG. The confocal experts also meet regularly at national meetings.

# Overview of all VivaScope® Products

## Devices for in vivo use

**VivaScope® 1500:** The non-invasive VivaScope 1500 provides a view into the epidermis down to the upper reticular dermis. Black and white images of the individual skin layers are generated.

**VivaScope® 3000:** The VivaScope 3000 is the manual model of the VivaScope series of products. Due to its compact design and low weight, it is especially well suited for a wide variety of applications and simplifies examining difficult to access skin regions.

**VivaCam®:** The digital dermatoscopic camera VivaCam is an accessory of the in vivo devices and complements the confocal imaging technology by supplying dermoscopic images of the skin surface.

**Dermographix:** The system of Canfield Scientific allows you to create a standardized total body mapping documentation in a minimal period of time and with the highest degree of detail. The software quickly and intuitively leads the user through the scanning process and automatically captures images of predefined skin areas from head to toe. During the imaging process, the user is supported in the detection of newly developed nevi.

## Devices for ex vivo use

**VivaScope® 2500 Multilaser:** The VivaScope 2500 Multilaser makes it possible to subject large specimens of freshly sampled tissue to pathological analyses at cellular resolution and in approx. 9 minutes. Imaging requires little to no prior preparation and is realized in exactly defined optical cross-sections.

*VivaScope® 1500*

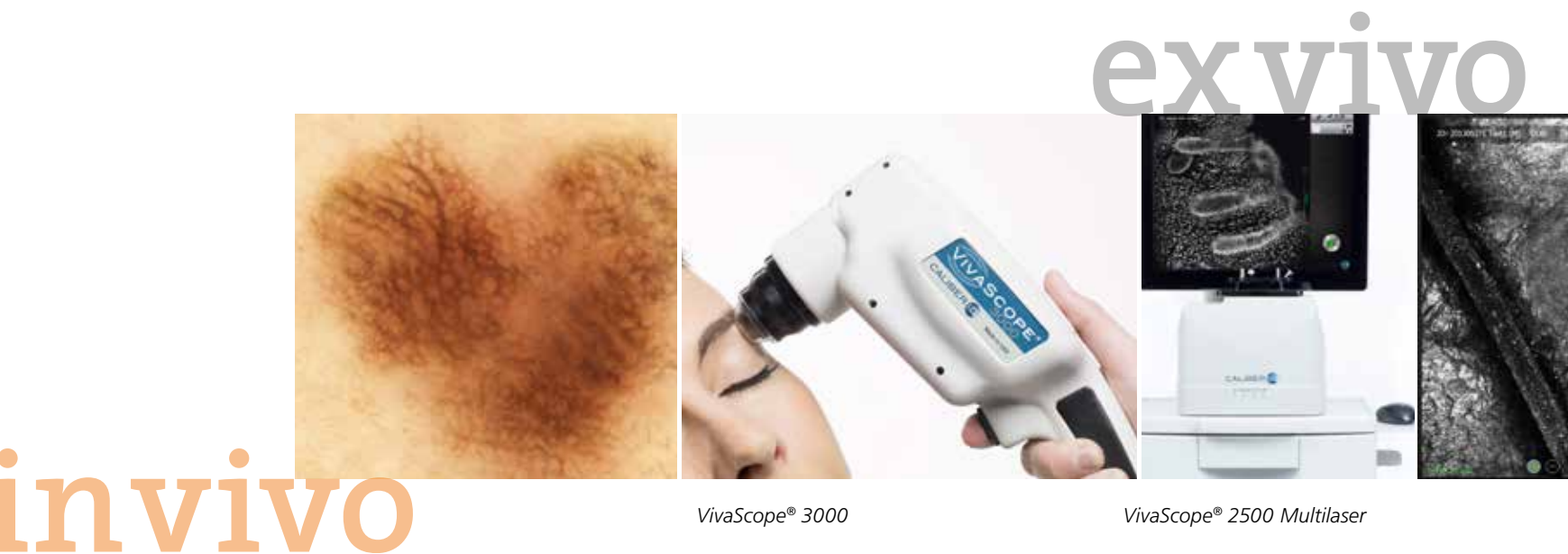
## Software and IT solutions

**VivaScan®:** VivaScan is the imaging application software (Windows compatible) for the VivaScope devices. This user-friendly software features an overview menu from which all confocal image and patient data can be depicted, processed, edited, and archived. The extended VivaScan-Version provides the management of patient data of the entire imaging chain (standardized total body mapping documentation, clinical image, dermoscopy and confocal microscopy) with the help of only one software surface. Thus an efficient and easy examination process is possible.

**VivaLAN:** VivaLan is a networked VivaScope solution. This system is intended to facilitate and coordinate the scheduling, imaging and reviewing of images within a practice, clinic or research facility where multiple VivaScopes and/or viewing workstations can be in use. VivaLan is configured to archive and store clinical, dermoscopic and confocal images centrally on a powerful server in order to provide an efficient workflow.

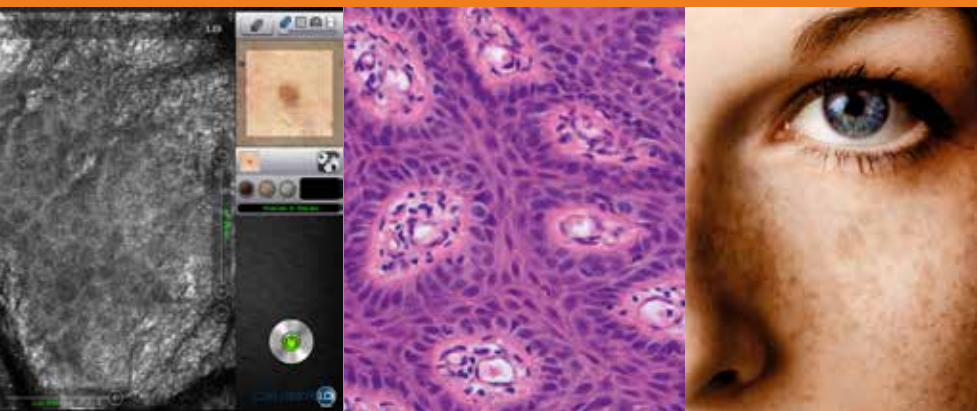
**VivaNet®:** VivaNet is a DICOM-compliant service for the storage, retrieval and transfer of VivaScope images. When using VivaNet, the dermatologist first compiles the patient's confocal images and then sends these to the VivaNet server via an encrypted private network through the Internet. The responsible dermatopathologist is able to retrieve the images immediately and return his or her assessment.

**ConfoScan:** ConfoScan is an image quantification utility. The quantification parameters of the confocal images can be digitized and the image values can then be depicted numerically.



*VivaScope® 3000*

*VivaScope® 2500 Multilaser*



**VivaScope**

Stahlgruberring 5  
81829 Munich  
Germany

Phone: +49 (0)89 420 96 -280

Fax: +49 (0)89 420 96 -201

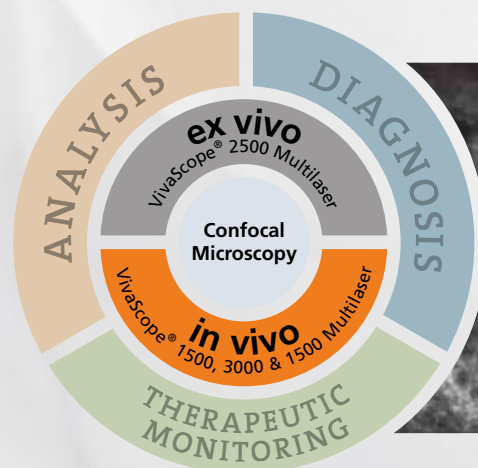
Email: [info@vivascope.eu](mailto:info@vivascope.eu)

**Technical Service**

Phone: +49 (0)89 420 96 -271

Email: [service@vivascope.eu](mailto:service@vivascope.eu)

Please visit [www.vivascope.eu](http://www.vivascope.eu)  
for additional information.



**VIVASCOPE**